

# Reduced Appearance of Under-eye Bags With Twice-daily Application of Epidermal Growth Factor (EGF) Serum: A Pilot Study

Rachel Seidel BA,<sup>a</sup> and Ronald L. Moy MD FAAD<sup>b,c</sup>

<sup>a</sup>Georgetown University School of Medicine, Washington, DC

<sup>b</sup>Keck School of Medicine of the University of Southern California, Los Angeles, CA

<sup>c</sup>Moy-Fincher-Chipps Dermatology, Beverly Hills, CA

## ABSTRACT

**Background:** Under-eye bags are a common manifestation of age and a frequent complaint among patients who no longer feel youthful. Non-invasive topical agents are largely ineffective at reducing their appearance.

**Objective:** We studied the ability of a topical serum containing epidermal growth factor (EGF) to minimize the appearance of under-eye bags.

**Methods:** A single-center clinical trial was performed on eighteen volunteer male and female patients with under-eye bags. Subjects applied EGF serum to the infraorbital area twice daily for 12 weeks. At each visit, subjects were evaluated using clinical photography and written self-assessment. A grade on the Merz Infraorbital Hollowness Scale was also given and two independent, blind investigators assigned an Investigator's Global Assessment (IGA) score. At the trial's end, patients shared their final evaluation and perception of results with a questionnaire.

**Results:** Sixteen subjects completed the trial. The final average Merz grade was 1.63 (SEM = .273), statistically significantly lower than the mean baseline average of 2.06 (SEM = .232) ( $P = .0019$ ). A reduction in average IGA score was also significant ( $P < .0001$ ). Average initial IGA was 2.75 (SEM = .270) and average final IGA was 2.00 (SEM = .310). All but two subjects reported improvement at the final visit. Improvement was quantified as 76-100% by two subjects, 50-75% by three subjects, and 25-49% by nine subjects. Eleven subjects classified their under-eye bags as milder at the end of the trial compared to the first visit. Seven subjects reported greater satisfaction with their overall facial appearance. Of the subjects who had used other topical treatments in the past, two reported the serum to be "significantly better" and four said it was "better" in treating their under-eye bags.

**Conclusion:** Our results offer evidence that topical EGF can reduce the appearance of under-eye bags.

*J Drugs Dermatol.* 2015;14(4):xxx-xxx.

## INTRODUCTION

With age, lower eyelid skin laxity leads to sagging of the infra-orbital area, a feature referred to commonly as "under-eye bags." Research has shown that the presence of this condition can detrimentally influence first impressions and general public perception. Understandably, the conflict between what is inferred and the patient's true character can be a significant source of distress and feelings of one's appearance can decline to the point of impairing self-esteem.

Though sometimes seen in younger patients owing to genetic influences, the overwhelming majority of under-eye bags result from age-related processes that accelerate over time. Changes in the extracellular matrix and loss of key structural proteins collagen and elastin cause the skin to lose structural support and elasticity.<sup>1</sup> Incapable of countering gravitational forces, skin overhangs beyond the lid margins, forming palpebral bags.

Laser resurfacing is a popular modality for the treatment of under-eye bags because it triggers an inflammatory process that ultimately leads to the synthesis of collagen and elastin.<sup>2</sup> How-

ever, the process of tissue ablation is not without peri-operative discomfort, a variable recovery period and an array of potential side effects. Knowing this, we investigated a less invasive treatment capable of producing similar changes in the extracellular matrix while circumventing the need to inflict damage to tissue.

Known for its ability to promote neocollagenesis and dermal thickening, epidermal growth factor (EGF) is released during the process of inflammation and wound healing and has cytoprotective, anti-apoptotic and mitogenic activity during the course of normal cellular development.<sup>3</sup> Topical EGF in various applications has been well tolerated, though its efficacy in treating under-eye bags has not been thoroughly studied. As a result, we performed a clinical trial using a synthetic, barley-derived EGF to investigate its effect on the appearance of under-eye bags in volunteer patients.

## METHODS

A single-center clinical trial was performed on eighteen self-selected subjects (13 women, 5 men, mean age 52) with evidence of under-eye bags on clinical exam. Sixteen subjects self-report-

ed their racial background as Caucasian, one as South Asian and another as Hispanic. Seven subjects reported trying one or several non-prescription topical agents for their condition in the past, while all remaining subjects denied any intervention prior to study start. Informed consent of the format commonly utilized by the Western Institutional Review board was obtained from all patients. Standard Operating Procedures for Clinical Research in accordance with the Moy-Fincher-Chipps oversight committee and Good Clinical Practice were observed.

Inclusion criteria were healthy men and women aged 30-70 years old with evidence of under-eye bags on clinical exam, determined by a score of 1 through 4 on the Merz Infra-Orbital Hollowness Scale (Merz Aesthetics) (Figure 1). Patients were further required to be able and willing to comply with the treatment regimen and follow-up obligations. Exclusion criteria included pregnancy, lactation, and receipt of invasive procedures (botulism toxin, fillers, laser resurfacing, autologous fat transfer, blepharoplasty) in the periocular region within six months prior to study start.

The trial involved twice-daily application of a 5ppm bioengineered, barley-derived, human synthetic EGF serum (DNA Regeneration Serum, DNA EGF Renewal, Oxnard, CA) to the infra-orbital region over 12 weeks. During the course of the trial, all patients refrained from the use of tretinoin, retinol and other vitamin A derivatives as well as the receipt and application of any treatment or topical product to the infra-orbital region. Evaluation of results was aided by the use of clinical photography using standard Canfield equipment performed at baseline and all subsequent visits.

At the initial appointment, clinical photography was performed using Canfield equipment. Patients were asked to fill out a questionnaire that allowed them to personally rate the severity of their condition (0 = none, 1 = very mild, 2 = mild, 3 = moderate, 4 = severe, 5 = very severe) and their overall feelings toward their facial appearance (0 = very dissatisfied, 1 = dissatisfied, 2 = neither satisfied nor dissatisfied, 3 = satisfied, 4 = very satisfied). The primary investigator assigned each subject a baseline grade using the Merz Intraorbital Hollow Scale to quantify the severity of under-eye bags. Two independent evaluators then assigned the subject an Investigator's Global Assessment score

(0 = none, 1 = very mild, 2 = mild, 3 = moderate, 4 = severe, 5 = very severe) and a mean value was calculated.

Subjects were evaluated at four-week intervals. At each visit, patients completed a questionnaire rating overall assessment of improvement and satisfaction with the treatment regimen. Free-form questions were also included to allow for more specific descriptions of perceived effects. Clinical photography was also completed at each follow-up.

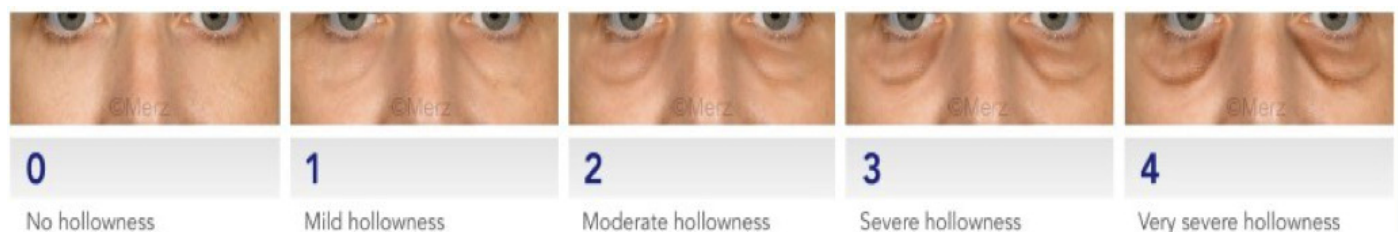At the final visit, subjects were asked to complete an additional questionnaire that asked their overall perception of treatment efficacy. Subjects quantified improvement as 0-24%, 25-49%, 50-75%, or 76-100% improved from baseline. They were also asked to rate the severity of their condition and feelings toward their facial appearance using the same scales used in the initial survey. The patients who had used topical agents for their under-eye bags prior to the start of the study were additionally asked to rate the EGF serum as 'significantly better,' 'better,' 'the same,' 'worse,' or 'significantly worse' in comparison. As at the initial appointment, the primary investigator used the Merz Infra-orbital Hollowness Scale to assign a final grade to each subject. Two independent evaluators assigned each patient a final IGA score, from which a mean was calculated.

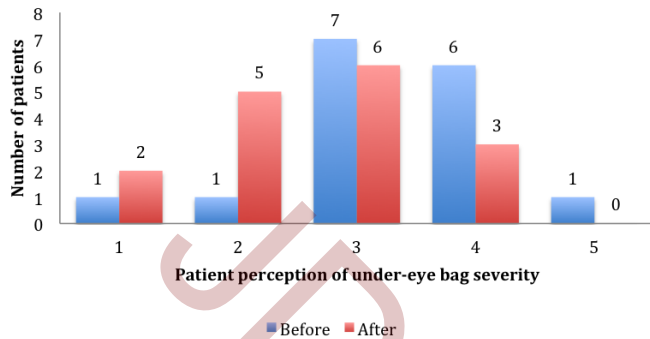
"Areas of thin skin, such as beneath the eyes, are particularly susceptible to sagging in response to reductions in the elastic and supportive properties of the extracellular matrix."

## RESULTS

Sixteen of the original eighteen subjects completed the trial. Two were lost to follow-up. At the start of the trial, one subject classified their under-eye bags as very severe (5), six as severe (4), seven as moderate (3), one as mild (2) and one as very mild (1). When asked to rate the severity of their under-eye bags at the end of the trial using the same system, eleven of the sixteen subjects chose a milder description. The number of subjects who selected each severity rating before and after the

**FIGURE 1.** Merz Infra-Orbital Hollowness Scale

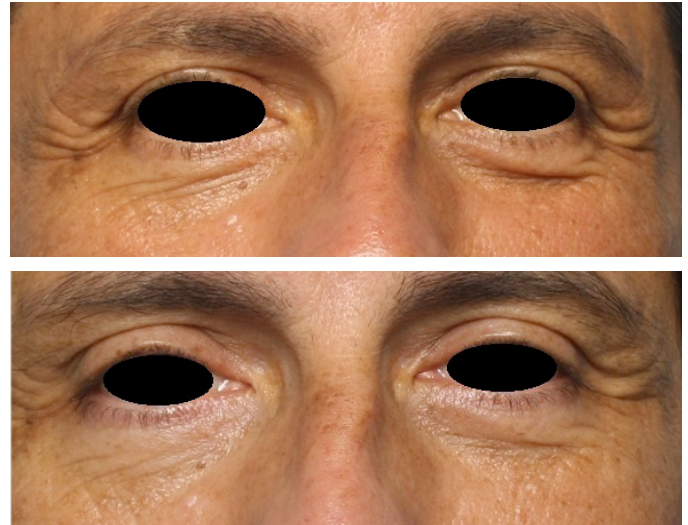


**FIGURE 2.** Comparison of eye bag severity as perceived by patient before and after EGF serum regimen.

trial is illustrated in Figure 2. Compared to how they felt about their overall facial appearance at the start of the trial, seven subjects stated that they were more satisfied at the final visit. Three of these subjects reported that they were “satisfied” with their appearance after having previously reported being “dissatisfied” at the beginning of the trial. One subject went from “dissatisfied” to “neither satisfied nor dissatisfied,” one from “neither satisfied nor dissatisfied” to “satisfied,” and two from “satisfied” to “very satisfied.”

When asked to rate the efficacy of the EGF serum, all but two subjects reported improvement. Of those subjects who perceived improvement, two reported “great improvement,” one saw “very good” improvement, four reported “good improvement” and the remaining nine subjects stated they saw “moderate improvement.” No subject quantified their improvement as “poor.” Improvement from baseline was quantified by two of these subjects as 76-100%, 50-75% by three subjects, and 25-49% by nine subjects. The average time at which improvement was first perceived was 3.67 weeks. Overall improvement among our subjects was well visualized in side-by-side before and after photographs, one of which is depicted in Figure 3. When asked if they would recommend the use of EGF serum for under-eye bags, thirteen subjects (81.2%) said yes. When the seven subjects who reported prior use of topical agents were asked to compare the efficacy of EGF serum in reducing the appearance of their under-eye bags, two reported the serum to be “significantly better” and the remaining four said it was “better.”

At the start of the study, the average score on the Merz Infraorbital Hollowness Scale among all subjects was 2.06 (SEM = .232). At the end of the trial, the average Merz score was reduced to 1.63 (SEM = .272). A one-tailed paired student t-test using values of initial and final Merz scores for each patient generated a *P*-value of .0019, verifying this mean difference as statistically significant. A similar trend was also seen when comparing initial and final scores on the Investigator’s Global Assessment (IGA). The average baseline IGA score among those subjects who completed the entire 12-week regimen was 2.75 (SEM =

**FIGURE 3.** Improvement in under-eye bags after 12 weeks of twice-daily infraorbital EGF serum application.**TABLE 1.****Average Merz Infraorbital Hollowness (MIH) Grade and Investigator Global Assessment (IGA) score at Baseline and Final Visit**

	Baseline	Final Visit
Average MIH grade	2.06 (SEM = .232)*	1.63 (SEM = .272)*
Average IGA score	2.75 (SEM = .270)**	2.00 (SEM = .310)**

\**P* = .0019\*\**P* < .0001

.270). At the final visit, the average IGA score was found to be 2.00 (SEM = .310). Using baseline and final IGA values for each patient and a one-tailed, paired student t-test, this difference was also found to be statistically significant with a *P*-value of < .0001. A summary of these statistics can be seen in Table 1.

## DISCUSSION

The periorbital region is one of the first areas of the face to show signs of aging, usually in the mid to late 30s.<sup>4</sup> Along with other changes to the orbit, such as the development of rhytides and hyperpigmentation, palpebral bags are a common complaint among individuals who feel their appearance is no longer youthful.<sup>1</sup> Because they are so common and also a frequent source of insecurity, a plethora of treatments aimed at reducing the appearance of under-eye bags are available. Invasive and minimally invasive methods such as lower eyelid blepharoplasty, radiosurgery, autologous fat transfer and laser resurfacing procedures are successful, yet carry a wide range of surgical risks and do not consistently obtain a rejuvenated appearance for the patient.<sup>5-7</sup> Despite the abundance of over the counter topical agents available, their general efficacy is questionable.

Under-eye bags that develop with age are the clinical manifestation of lower eyelid dermatochalasis, a term that refers to an excess of skin in the infra-orbital area.<sup>1</sup> In this case, excess is a relative term and refers to the appearance of redundant skin overlying a reduced volume of tissue. With age, atrophy of subcutaneous fat in the lower periorbital region reduces the skin's structural support. This causes the lower eyelid skin to become lax and overhang the lid margin.<sup>5</sup> Compounding this process is the fact that aging skin is thin and less elastic, rendering it more susceptible to sagging and the pull of gravitational forces over time.<sup>1</sup>

Skin thinning and loss of elasticity is a generalized process that occurs with age and is the result of ultraviolet-induced degeneration and age-related degeneration.<sup>1</sup> These processes, intrinsic and extrinsic, act independently to disrupt the physical integrity of the skin. Most affected are collagen and elastin, extracellular matrix proteins that provide integrity and elasticity to the skin, respectively.<sup>8</sup>

Dermal atrophy, which occurs universally in aged skin, results from degeneration of and failure to properly synthesize collagen.<sup>9</sup> Matrix metalloproteinases (MMPs), enzymes responsible for degrading collagen, grow increasingly less responsive to intrinsic regulatory signals as cells age, resulting in accelerated collagen breakdown and residual fibers that are highly disorganized.<sup>10,11</sup> Several histologic studies have demonstrated these findings.<sup>12-18</sup> Though the mechanism remains unclear, collagen synthesis also gradually declines beginning in the third or fourth decade of life and so is unable to balance the rate of collagen degeneration.<sup>19</sup> The ensuing collagen deficiency is further exacerbated by chronic ultraviolet radiation (UVR) exposure. Though collagen biosynthesis is unaffected by UVR, chronic exposure has been shown to increase the activity of MMPs.<sup>11,20,21</sup> This explains the general reduction in type I collagen seen in photo-damaged skin and also the sparse distribution, fragmentation and improper organization of fibers.<sup>22-25</sup>

The end result of both the intrinsic and extrinsic aging processes is a reduced number of disorganized collagen fibers that are less able to provide structural support for the skin. The skin loses its resiliency and cannot adequately counter gravitational forces, causing it to sag.<sup>26</sup> Sagging of the skin is exacerbated by comparable changes in the elastic fiber network. Degeneration and impaired organization of elastic fibers is attributed to the same age-dependent increase in MMP expression underlying collagen deficiency.<sup>20</sup> Along with solar elastosis, the accumulation of abnormal elastotic material in the upper and middle dermis in response to UVR, this process underlies the marked reduction in skin elasticity seen with age.<sup>27-29</sup>

Areas of thin skin, such as beneath the eyes, are particularly susceptible to sagging in response to reductions in the elastic

and supportive properties of the extracellular matrix. Because under-eye bags develop, in large part, from changes in these biochemical properties, much of the success of laser resurfacing in reducing their appearance stems from its ability to promote collagen and elastin synthesis. By inducing microscopic thermal injuries to the skin, lasers such as the CO<sub>2</sub> and Er:YAG trigger an innate inflammatory and wound healing response.<sup>30</sup> Dermal remodeling ensues and involves the synthesis of new, compact collagen and elastin.<sup>2</sup> Evidence of neocollagenesis and neolastogenesis has been documented for at least 18 months after CO<sub>2</sub> laser resurfacing and is believed responsible for improvements in dermatochalasis following treatment of the periocular area.<sup>2,31</sup> Despite their success, however, lasers are associated with variable degrees of peri- and post-treatment pain. They also have the potential to cause a wide array of side effects including redness, bruising, infection and swelling, as well as transient and chronic hyperpigmentation, particularly in dark-skinned patients.<sup>32,33</sup>

The results of our study on EGF serum demonstrate efficacy of a novel, non-invasive treatment for under-eye bags, which has proven safe and associated with minimal risk in prior studies (34)(3). As with laser resurfacing, we attribute our results to the promotion of neocollagenesis. However, visible improvement was attained in this study without inflicting tissue injury.

EGF is released during the natural course of inflammation and wound healing and is a potent stimulus for the proliferation of mesenchymal and epithelial cells (Kwon). Among its cytoprotective, anti-apoptotic and mitogenic effects, EGF is pro-mitotic for fibroblasts, one of several cell types responsible for collagen synthesis.<sup>3</sup> Several *in vitro* and *in vivo* studies have demonstrated the ability of EGF to promote collagen deposition.<sup>35-37</sup> Hiramatsu et al. demonstrated an increase in wet weight and collagen content following EGF injections using cotton pellet granulomas in rats.<sup>36</sup> Another study showed dose-dependent increases in collagen accumulation following daily subcutaneous injections of EGF into sponge-induced rat granulomas and concluded the effect was the direct result of fibroblast proliferation.<sup>37</sup> Collagen deposition and dermal granulation have also been shown to occur following topical administration of EGF in wound models. A study by Kwon et al. showed increased expression of prolyl 4-hydroxylase, a marker of collagen synthesis, in full-thickness wounds treated with recombinant EGF ointment.<sup>38</sup>

The ability of EGF to increase dermal collagen explains the reduced appearance of under-eye bags in our study. We believe that twice-daily topical application of EGF thickened the dermis in the infra-orbital area, as occurred in wound and granulation tissue models. Evidence for this can be found in a recently performed study that examined the ability of EGF serum to reduce ecchymoses in senile purpura patients and

which demonstrated a statistically significant increase in average skin thickness with ultrasound measurements.<sup>39</sup> In addition to increasing the amount of collagen present, newly synthesized fibers are deposited in the appropriate orientation. These changes to the collagen matrix improve its ability to support the overlying skin and impart resiliency, properties critical to the prevention of sagging.

Of note, many of the subjects in our study said they noticed an improvement in infraorbital dark circles. Referred to clinically as periorbital hyperpigmentation, dark circles commonly go hand in hand with dermatochalasis, as skin laxity imparts a shadow on the lower eyelid.<sup>40</sup> Thin skin can also cause dark circles by allowing greater visibility of the orbicularis oculi muscle and underlying vasculature.<sup>40</sup> Considering its ability to thicken the skin and reduce dermatochalasis, the ability of EGF to improve periorbital hyperpigmentation from these etiologies is not surprising. By promoting epidermal proliferation, EGF is also able to improve periorbital hyperpigmentation stemming from hypermelanosis, as occurs with genetic predisposition or following inflammation. By promoting epidermal turnover, EGF triggers more rapid removal of melanin contained within keratinocytes.<sup>41-43</sup> Minimization of dark circles in several of our subjects likely intensified the improvement seen in under-eye bags from dermal thickening alone.

The results of our study demonstrate the ability of topically applied EGF serum to reduce the appearance of under-eye bags. Efficacy in treating this condition is significant in light of the paucity of currently available noninvasive treatments for this indication. However, given our study's limited sample size, a repeat trial with a larger population is warranted. Additional investigation is also needed to determine the optimal frequency and duration of application to optimize results.

Looking forward, we believe supplementing EGF serum with interleukin-1 $\beta$  (IL1 $\beta$ ), a cytokine shown to increase elastin gene transcription and promote elastin synthesis, could result in even greater improvement.<sup>44</sup> Topical IL1 $\beta$  has proven safe in previous studies.<sup>45</sup> In concert, EGF and IL1 $\beta$  could reverse abnormalities of both collagen and elastin and thereby improve skin elasticity as well as integrity. Considering the role of MMPs in collagen and elastin degradation, we believe supplementing EGF serum with a cream containing DNA repair enzymes may have prophylactic benefit by silencing MMP genes.<sup>46</sup> The combination of DNA repair enzymes and EGF would allow for simultaneous prevention of EC matrix degradation and repair of damage already incurred.

## DISCLOSURES

Dr. Ronald Moy owns stock and is the scientific advisor of DNA EGF Renewal, which manufactures the serum studied in this trial.

## REFERENCES

- DeAngelis DD, Carter SR, Seiff SR. Dermatochalasis. *Int Ophthalmol Clin*. 2002;42(2):89-101.
- Alster TS, Bellew SG. Improvement of Dermatochalasis and Periorbital Rhytides With a High-Energy Pulsed CO<sub>2</sub> Laser: A Retrospective Study. *Dermatol Surg*. 20-4;30(4 Pt 1):483-7
- Schouest JM, Luu TK, Moy RL. Improved texture and appearance of human facial skin after daily topical application of barley-produced, synthetic, human-like epidermal growth factor (EGF) serum. *J Drugs Dermatol*. 2012;11(5):613-20.
- Trepsat F. Periorbital rejuvenation combining fat grafting and blepharoplasties. *Aesthetic Plast Surg*. 2003;27:243-253.
- Ciuci PM, Obagi S. Rejuvenation of the periorbital complex with autologous fat transfer: current therapy. *J Oral Maxillofac Surg*. 2008;66:1686-1693.
- Pak, CS, Lee, YK, Jeong JH, et al. Safety and efficacy of elthera in the rejuvenation of aging lower eyelids: a pivotal clinical trial. *Aesthetic Plast Surg*. 2014;38(5):861-8.
- Kranendonk S, Obaqi S. Autologous fat transfer for periorbital rejuvenation: indications, technique, and complications. *Dermatol Surg*. 2007;33(5):572-578.
- Uitto J. The role of elastin and collagen in cutaneous aging: Intrinsic aging vs. photoexposure. *J Drugs Dermatol*. 2008;7:s12-s16.
- Farage, M, Miller, K, Maibach, H. *Textbook of Aging Skin*. 1<sup>st</sup> ed. New York: Springer-Verlag. 2010.
- Varani J, Warner RL, Gharaee-Kermani M, et al. Vitamin A antagonizes decreased cell growth and elevated collagen degrading matrix metalloproteinases and stimulates collagen accumulation in naturally aged human skin. *J Invest Dermatol*. 2000;114:480-6.
- Varani, J, Spearman, D, Perone, P, et al: Inhibition of type I procollagen synthesis by damaged collagen in photoaged skin and by collagenase-degraded collagen in vitro. *Am J Pathol* 2001, 158: 931-942
- Smith JG, Davidson EA, Clark WM. Alterations in human dermal connective tissue with age and chronic sun damage. *J Invest Dermatol*. 1962;39:347-356.
- Lavker RM. Structural alterations in exposed and unexposed aged skin. *J Invest Dermatol*. 1979;73:559-566.
- Pieraggi MT, Julian M, Bouissou H. Fibroblast changes in cutaneous aging. *Virchows Arch A Pathol Anat Histopathol*. 1984;402:275-287.
- Marks R. *Sun-Damaged Skin*. London: Martin Dunitz. 1992.
- Lavker RM, Gilchrist BA. Cutaneous aging: chronologic versus photoaging. *Photoaging*. Cambridge: Blackwell. 1995.
- Montgomery, PO. A characterization of basophilic degeneration of collagen by histochemical and microspectroscopic procedures. *J Invest Dermatol*. 1955;24(2):107-10.
- Bonta M, Daina L, Muşiu G. The process of ageing reflected by histological changes in the skin. *Rom J Morphol Embryol* 2013, 54:797-804.
- Uitto, J. Molecular pathology of collagen in cutaneous diseases. *Adv Dermatol*. 1991;6:265-86
- Fisher GJ, Quan T, Purohit T, et al. Collagen fragmentation promotes oxidative stress and elevates matrix metalloproteinase-1 in fibroblasts in aged human skin. *American Journal of Pathology*. 2009;174(1):101-114.
- Makrantonaki E, Zouboulis CC. Molecular mechanisms of skin aging state of the art. *Ann N.Y. Acad Sci*. 2007;1119:40-50.
- Fourtanier, A, Berrebi, C. Miniature pig as animal model to study. photoaging. *Photochem. Photobiol*. 1989;50:771-784.
- Contet-Audonneau JL, Jeanmaire C, Pauly G (1999) A histological study of human wrinkle structures: comparison between sun-exposed areas of the face, with or without wrinkles, and sun-protected areas. *Br J Dermatol*. 140:1038-1047
- Talwar HS, Griffiths CE, Fisher GJ, Hamilton TA, Voorhees JJ. Reduced type I and type III procollagens in photodamaged adult human skin. *J Invest Dermatol*. 1995;105:285-290.
- Trautinger, F, Mazzucco, K, Knobler, RM et al. UVA- and UVB-induced changes in hairless mouse skin collagen. *Arch Dermatol Res*. 1994;286(8):490-4.
- Giacomini PU, Rein G (2004) A mechanistic model for the aging of human skin. *Micron*. 35:179-184.
- Hussain SH, Limthongkul B, Humphreys T. The biomechanical properties of the skin. *Dermatol Surg*. 2013;39:193-203.
- Watson REB, Griffiths CEM, Craven NM, Shuttleworth CA, Kielty CM. Fibrillin-rich microfibrils are reduced in photoaged skin. Distribution at the dermal-epidermal junction. *J Invest Dermatol*. 1999;112:782.

29. Varani J, Dame M. K, Rittie L, et al. Decreased collagen production in chronologically aged skin: roles of age-dependent alteration in fibroblast function and defective mechanical stimulation. *Am. J. Pathol.* 2006;168(6):1861–1868
30. Waibel, J. Fractional laser resurfacing now and in the future: clinical, cellular, and histologic review. *Cosmet Dermatol.* 2012;25:43-47
31. Walia S, Alster TS. Prolonged clinical and histologic effects from CO2 laser resurfacing of atrophic acne scars. *Dermatol Surg* 1999;25:926–30.
32. Graber EM, Tanzi EL, Alster TS. Side effects and complications of fractional laser photothermolysis: experience with 961 treatments. *Dermatol Surg.* 2008;34:301–5
33. Berlien, HP, Müller, G. *Applies Laser Medicine.* Berlin/Heidelberg: Springer-Verlag. 2003.
34. Berlanga-Acosta J, Gavilondo-Cowley J, Lopez-Saura P, et al. Epidermal growth factor in clinical practice: a review of its biological actions, clinical indications and safety implications. *Int Wound J.*2009;6:331–346.
35. Buckley A, Davidson JM, Kamerath CD, Wolt TB, Woodward SC. Sustained release of epidermal growth factor accelerates wound repair. *Proceedings of the National Academy of Sciences of the United States of America.* 1985;82(21):7340–7344.
36. Hiramatsu M, Hatakeyama K, Minami N, Kumegawa M. Increase in collagen synthesis of cotton pellet granuloma in rats by epidermal growth factor. *Jpn J Pharmacol.* 1982;32(1):198–201.
37. Laato M, Kähäri VM, Niinikoski J, Vuorio E. Epidermal growth factor increases collagen production in granulation tissue by stimulation of fibroblast proliferation and not by activation of procollagen genes. *Biochem J.* 1987;247:385-8.
38. Kwon YB, Kim HW, Roh DH, Yoon SY, Baek RM, Kim JY, et al. Topical application of epidermal growth factor accelerates wound healing by myofibroblast proliferation and collagen synthesis in rat. *J Vet Sci.* 2006;7:105–9.
39. McKnight, B, Seidel, R, Moy, RL. Epidermal growth factor in the prevention of dermatoporosis and the treatment of senile purpura. (submitted)
40. Roh MR, Chung KY. Infraorbital dark circles: definition, causes, and treatment options. *Dermatol Surg.* 2009;35:1163–1171.
41. Tolleason WH. Human melanocyte biology, toxicology, and pathology. *J Environ Sci Health C Environ Carcinog Ecotoxicol Rev.* 2005;23:105–161.
42. Woo, WJ, Bang, SH, Min, KH et al. Epidermal growth factor and epidermal growth factor signaling attenuate laser-induced melanogenesis. *Dermatol Surg.* 2013;39(12):1903-11
43. Brown GL, Curtsinger L, 3rd, Brightwell JR, et al. Enhancement of epidermal regeneration by biosynthetic epidermal growth factor. *J Exp Med.* 1986;163(5):1319-1324.
44. Comper, W. *Extracellular Matrix Volume 2: Molecular components and interactions.* Amsterdam: Overseas Publishers Association. 1996.
45. Robson MC, Abdullah A, Burns BF, et al. Safety and effect of topical recombinant human interleukin-1B in the management of pressure sores. *Wound Rep Regen.* 1994; 2:177–181.
46. Dong KK, Damaghi N, Plicart SD et al. UV-induced DNA damage initiates release of MMP-1 in human skin. *Exp Dermatol.* 2008;17(12):1037-44.

#### AUTHOR CORRESPONDENCE

**Ronald Moy MD FAAD**

E-mail:..... ronmoymd@gmail.com